

# EVALUATION OF A FLEXIBLE NEW LIQUID POLYMER WOUND DRESSING

Sherry H. Hsiung MD, Perry Robins MD

New York University, Department of Dermatology, New York, NY

## Abstract

Occlusive dressings are the foundation of wound care and have been shown to speed epithelialization and healing of surgical sites. Many different dressings have been introduced over the years including antibacterial ointments with gauze and adhesive, hydrocolloid bandages, and liquid adhesives. All of these have their limitations and advantages. We introduce our experience with a new organic polymer in solvent which when applied to a wound forms a flexible occlusive bandage. The material has been shown to have antimicrobial properties and be well-tolerated by patients.

## Introduction

For decades, it has been well-established that occlusive dressings facilitate wound epithelialization.<sup>1,3</sup> Through the maintenance of a moist environment, occlusive dressings enable more rapid resurfacing. Both hydrocolloid and polyurethane dressings, which have been traditional dressings in the past, have been shown to increase rate of healing.

In recent years, new wound dressings have been introduced as alternatives to traditional gauze and plastic with adhesives. Cyanoacrylates are compounds, initially launched in 1949, which polymerize to form an adhesive film<sup>4</sup> and have been marketed for the closure of lacerations in the place of sutures or staples.

We introduce a new organic polymer, which is applied to the wound in liquid form. The solvent evaporates leaving a transparent, occlusive wound dressing. The polymer forms a flexible, elastic barrier to protect the wound and has antimicrobial properties. Two different assays were performed to test the antimicrobial effectiveness of the compound. In both the pour-plate method and the enrichment assay, the organic compound in solvent was found to inhibit the growth of *Candida albicans*, *Aspergillus niger*, *Escherichia coli*, *Pseudomonas aeruginosa*, and *Staphylococcus aureus*. Each study was validated with the appropriate positive and negative controls.

## Case Studies

This new liquid adhesive, which is approved by the Federal Drug Administration, was used in approximately 100 surgically induced wounds common to a dermatologic surgery practice. In general, the bandage was very well-tolerated by the patients.

Case 1, skin biopsy: A 76-year old female with history of multiple non-melanomatous skin cancer presented to us with an erythematous papule on the left infralabial region of her face. She denied bleeding or irritation to the lesion. As the clinical suspicion for a basal cell carcinoma was high, a small shave biopsy was performed. After hemostasis was obtained with aluminum chloride, a thin layer of the liquid bandage was applied (Figure 1) and allowed to dry. The patient returned for follow-up one week later and noted that wound was nearly healed (Figure 1b).

Figure 1a. Liquid Bandage at Application.

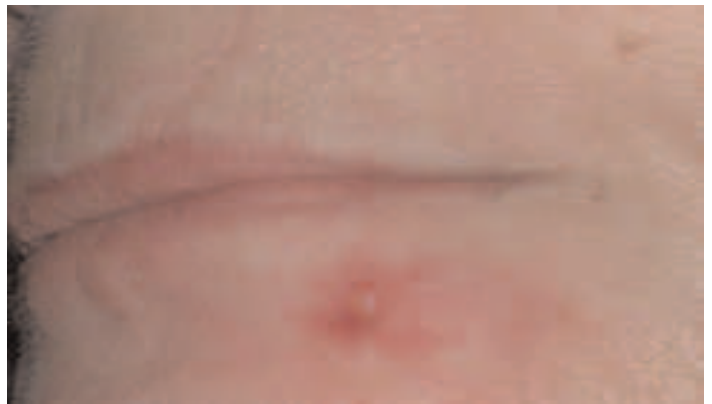
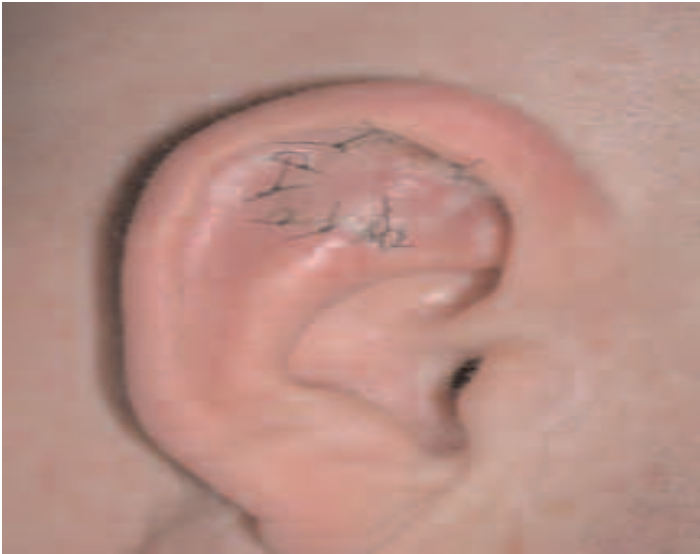
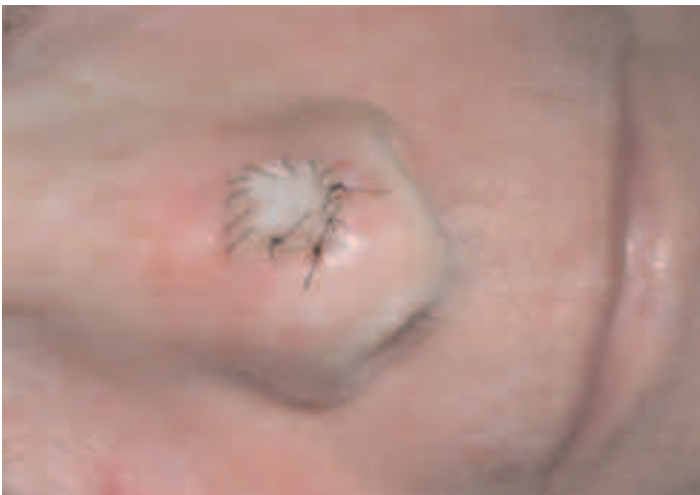Figure 1b. Wound Area Nearly Healed at 1 Week Follow-Up.



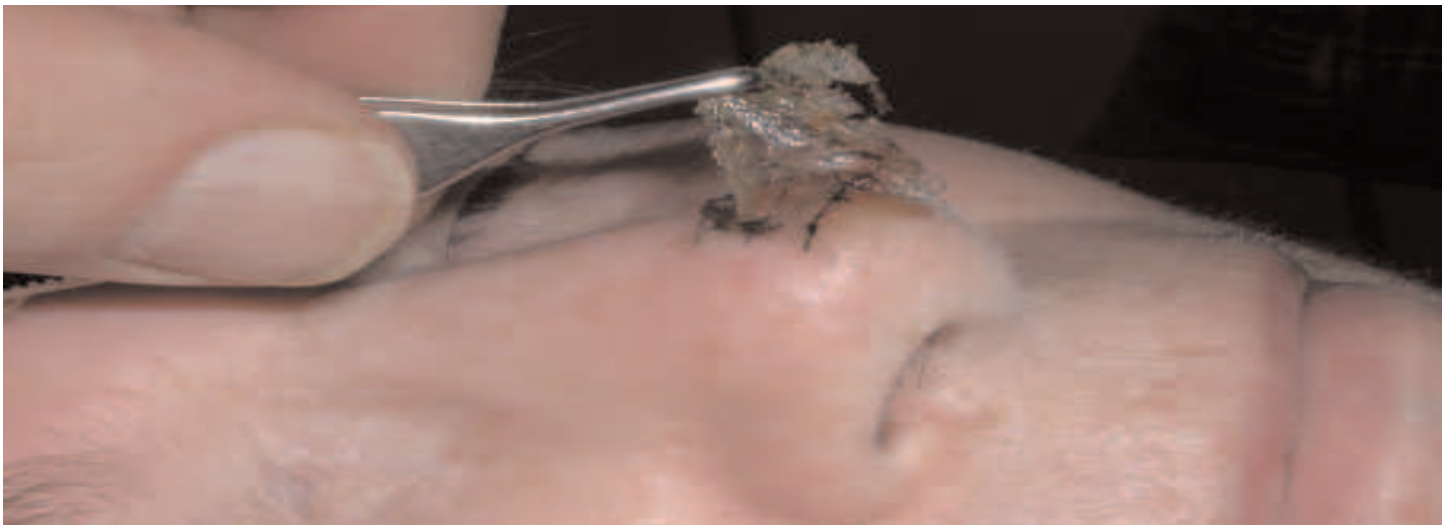
**Figure 2.** Ear at 1 Week After Surgery.



**Figure 3a.** Graft on Nose at 1 Week.



**Figure 3b.** The Occlusive Nature of the Film is Formed by the Polymer and Adherence of the Graft.

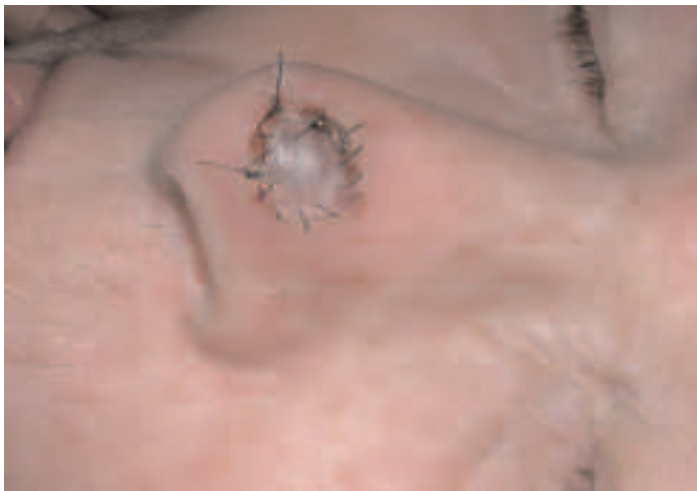


Case 2, rotation flap of the auricle: A 52-year old Caucasian male presented for Mohs micrographic surgical excision of a squamous cell carcinoma in situ, arising in a verruca on the right auricle. The tumor was removed in one stage. A rotational flap was used to repair the defect. The liquid adhesive was applied to the area and allowed to dry. A pressure bandage was used in the immediate 24-hour post-operative period, after which it was removed. The patient was also medicated with ciprofloxacin for one week after the post-operative period. The patient was seen one week after surgery, at which time the wound was healing well. The liquid adhesive bandage was intact (Figure 2).

Case 3, full-thickness skin graft: An 80-year old female presented for treatment of a basal cell carcinoma on the left tip of the nose. After 3 stages of Mohs surgery to remove the cancer, a full thickness skin graft from the left preauricular area was used to repair the defect. Immediately after suturing, the organic polymer dressing was applied and allowed to dry. A pressure bandage was applied for 24 hours, after which the patient was instructed to remove the pressure bandage only. No additional wound care was performed by the patient. Figure 3a shows the graft at one week, the occlusive nature of the film (Figure 3b) which is formed by the polymer and the adherence of the graft to the donor site (Figure 3c).

### Discussion

An ideal bandage for most dermatologic procedures provides an occlusive wound covering, which enhances the

**Figure 3c.** Donor Site.

speed of epithelialization. In addition, the dressing should have antimicrobial properties and be easy to care for. The traditional dressing of antibacterial ointment under gauze or non-adherent pad held in place with adhesive must be changed daily, at a minimum. This may be difficult for elderly or invalid patients and cumbersome for all patients. Depending upon the location, adhesive may not be feasible or tenable. Such locations may include the scalp, highly mobile joints, or difficult to reach areas. Allergic and irritant reactions to both the antibacterial ointments and adhesives are also commonly seen.

We introduce the use of a new liquid adhesive which dries to form an occlusive elastic covering. In the appropriate clinical circumstance the compound provides an ideal wound dressing, which is easy to use and protects the wound. The material is ideal for shave biopsies in locations where traditional bandages are difficult (ie, hair bearing locations or highly mobile joints) or areas which are difficult to reach (ie, mid back). In addition, the adhesive proves to be satisfactory for use over excisional wounds, flaps, and grafts. Finally, the dressing is also economical as it precludes the necessity of daily antibiotic ointment, dressing, and tape.

In our preliminary experience with this bandage there have been a few limitations. The application of the bandage can sting slightly if the patient has not been anesthetized. This is rarely an issue, however, as sites are typically anesthetized prior to the procedure. The liquid bandage may be removed by rubbing or washing of the surgical site, so patients must be instructed in the care of the site.

In addition, in cases where hemostasis has not been fully obtained, oozing under the occlusive dressing may cause maceration of the epidermis. This does not seem to impede the healing process, but can be distressing for the patient. Finally, although none of the patients to date has had a reaction, the incidence of allergic potential has not been established.

This new organic polymer has been very successful providing a near ideal bandage for multiple wound types found in the dermatologist's office. The compound is easy to apply and, unlike other liquid adhesives, forms a transparent, flexible, non-brittle barrier that bends with the surrounding skin. Its antimicrobial properties are an additional benefit. The dressing is easy for patients to care for and we have not observed allergic hypersensitivity. Further studies and larger patient experience will be needed to elucidate the long-term outcomes and potential complications for this new liquid adhesive.

Disclosure: Dr. Robins has stock in Medpak, LLC.

## References

1. Hindman CD, Maibach HI. Effect of air exposure and occlusion on experimental human skin wounds. *Nature*. 1963;200:377-8.
2. Nemeth AJ, Eaglstein WH, Taylor JR, et al. Faster healing and less pain in skin biopsy sites treated with an occlusive dressing. *Arch Dermatol*. 1991;127:1679-83.
3. Eaglstein WH, Davis SC, Mehle AL, Mertz PM. Optimal use of an occlusive dressing to enhance healing. *Arch Dermatol*. 1988;124:392-5.
4. Ardis AE. U.S. patent nos. 2467926 and 2467927, 1949.

### Address for Correspondence

Perry Robins MD  
NYU Medical Center,  
Department of Dermatology  
530 1st Ave Suite 7-H  
New York, NY  
Phone 212-686-4663